

HEAD AND NECK SCREENING CAMP

BY

DEPTT ENT & HNS

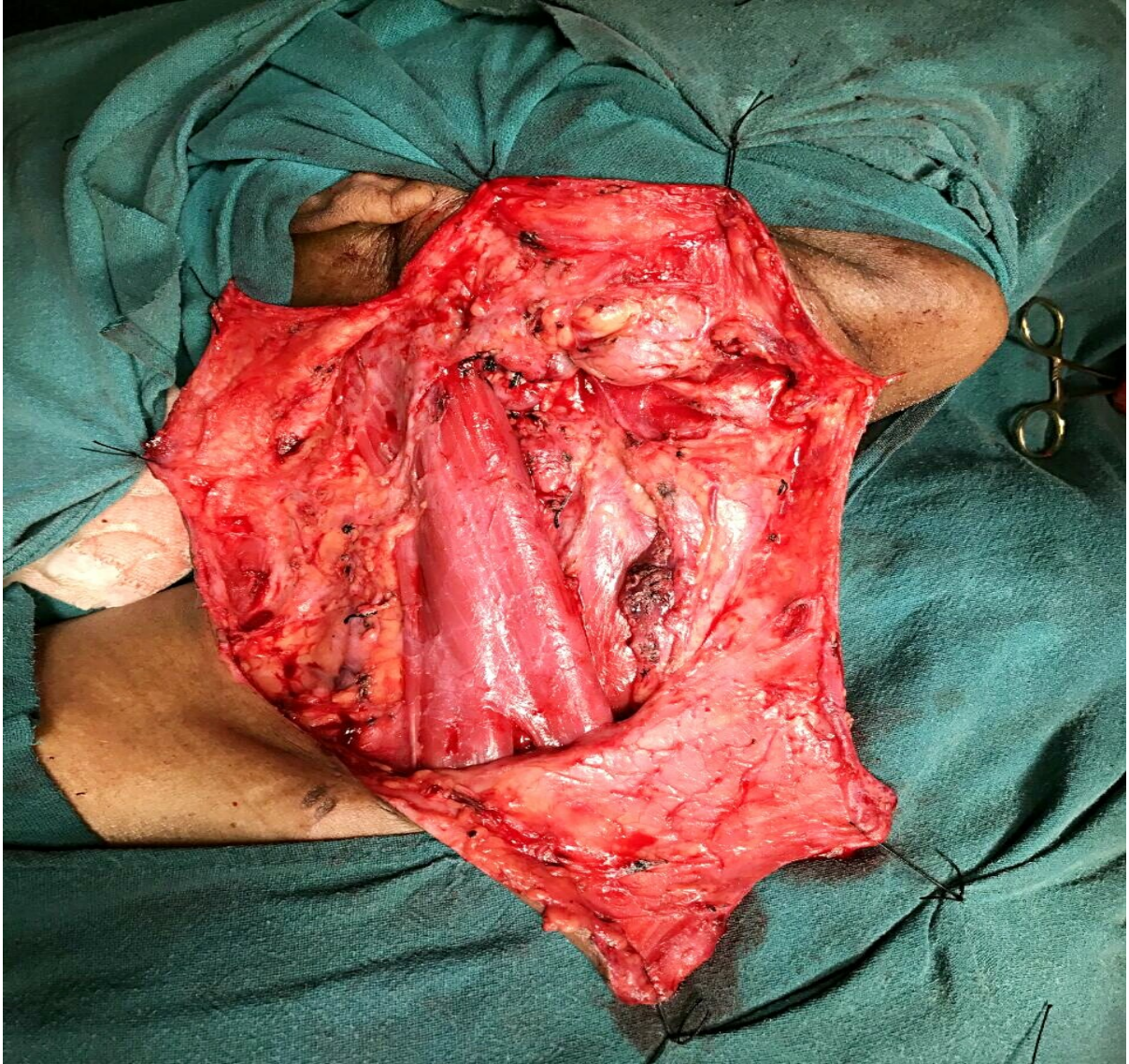
AT ESIC MODEL HOSPITAL SECTOR -24 NOIDA

**CASE OF CARCINOMA ORAL CAVITY T₂ N₁ M₀ (TONGUE
SUBSITE)
OPERATED BY
DEPPT OF ENT & HNS AT ESIC MODEL HOSPITAL SECTOR -
24 NOIDA**

ESIC MODEL HOSPITAL NOIDA UP – DEPTT OF ENT HEAD & NECK SURGERY WITH DEPTT OF ANESTHESIA PERFORMED RIGHT SIDE HEMIGLOSSECTOMY WITH IPSILATERAL TYPE 3 MODIFIED RADICAL NECK DISSECTION WITH TONGUE RECONSTRUCTION WITH ELECTRIVE TRACHEOSTOMY UNDER GENRAL ANESTHESIA ON 30/03/17.

PATIENT IS A 52YRS MALE, K/C/O CA ORAL CAVITY (SUBSITE TONGUE) WITH NECK NODE METASTASIS. (T₂N₁M₀). BIOPSY CAME WITH CLEAR MARGINS AND NODE POSITIVE. NOW TAKING PRALLY & PLANNED FOR RADIOTHERAPY IGRT 30 FRACTIONS AND

NECK DISSECTION



TONGUE SPECIMEN

